

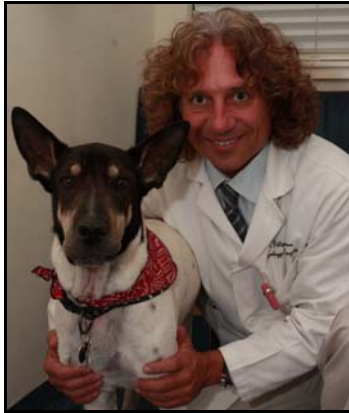# Diagnosis, Treatment & Prognosis of Disc Associated Wobbler Syndrome in Dogs

By Dr. Filippo Adamo, DVM, Dipl. ECVN, Veterinary Neurology Specialist  
President Bay Area VNC (Veterinary Neurology Neurosurgery Consulting)  
208 Santa Clara Way, San Mateo, California, USA 944033 (608)334-3713



Flppadamo@yahoo.com

www.bayareavnc.com



Dr. Filippo Adamo & his dog Pancio

*Dr. Adamo is European Board Certified Veterinary Neurologist and Neurosurgeon. During the last 20 years, he built up his neurological experience in both academia and private practice in both Europe and USA. Dr. Adamo has been a Board Certified Neurologist since 1997. Prior to moving to California, Dr. Adamo served from 2002 to 2007 as Clinical Assistant Professor in Neurology at the School*

*of Veterinary Medicine, University of Wisconsin. He then moved with his family to California where he served as Chief of Neurology at the Bay Area Veterinary Specialists in San Leandro until July 2009. As a chief of neurology at the University of Wisconsin, he developed many years of experiences in research and clinical neurology/ neurosurgery. Dr. Adamo developed an alternative cyclosporine medical treatment for Granulomatous meningoencephalomyelitis (GME) in dogs, designed a frameless guided stereotactic CT guided brain biopsy, investigated alternative medical therapy for brain meningioma in dogs and cats, and developed and tested the first artificial disc for the canine cervical spine. He has lectured and published extensively in the United States and Europe. His main areas of interest are brain inflammatory diseases, and brain and cervical spinal surgery. When not spending time with his son, and their dog (Pancio), Dr. Adamo enjoys playing Brazilian rhythm music and Aikido.*

## Introduction

Wobbler syndrome in dogs refers to a collection of disorders of the cervical vertebrae and intervertebral discs of large breed dogs resulting in cervical canal stenosis and spinal cord compression. All these different clinical entities result in the same clinical signs, mainly characterized by a typical wobbling gait (predominantly affecting the hind limbs), paresis and cervical pain. The most typical and predominant syndrome is the disc associated Wobbler syndrome (DAWS). DAWS, predominantly affects middle to older age, large-breed nonchondrodystrophoid dogs, particularly Doberman Pinschers. Doberman Pinschers may be predisposed to clinical cervical spinal cord compression by congenital relative vertebral canal stenosis with a loss of reserve space. Many other breeds have also been reported as being affected by this condition (including small dogs), and in one study of 90 dogs, where Doberman Pinschers were excluded, thirty-two breeds were represented, of which Labrador retrievers (13), Dalmatians (13) and Rottweilers (12) were the most commonly affected. The main factor in DAWS is the underlying chronic disc degenerative disease, which is also common in

Rottweilers. The C5-C6 and C6-C7 disc spaces are most commonly affected, with lesion in both interpaces present in about 20% of affected dogs.

## Pathogenesis

Although the pathogenesis of DAWS is not well understood, it is thought to be multifactorial including primary developmental abnormalities and secondary degenerative changes that lead to vertebral canal stenosis and spinal cord compression. Chronic degenerative disc disease seems to be such an important factor that the term "DAWS" has been suggested. Spinal cord compression in DAWS is often dynamic and secondary to a combination of degenerative disc diseases (leading to protrusion of the intervertebral disc) and the relative redundancy, relative hypertrophy, or "in folding" of the ligamentous structures (dorsal longitudinal ligament, dorsal annulus, interarcuate ligament and joint capsule) because of collapse of the disc space. The relative redundancy of the dorsal longitudinal ligament and the dorsal annulus results more often in ventrally located spinal cord compression. The relative redundancy of the interarcuate ligaments and joint capsules may result in dorsally located spinal cord compression, with or without osteoarthritis of the overloaded facets, or articular processes. Simultaneous narrowing of the intervertebral foramina because of disc space collapse may cause neurovascular compression at the foramina. Generally in-traction responsive lesion, the dorsal and/or ventral spinal cord compression may be reduced by the application of linear traction to the cervical spine which re-establishes disc width, flattens the relatively redundant soft tissue structures, and opens the narrowed foramina. In most dogs, 2-3 mm of distraction restores a normal disc width of 4-6 mm.

## Diagnosis - Clinical signs

Animal affected with DAWS are usually 4-8 years of age. The most common presentation of DAWS is ataxia (lack of gait coordination), which is most severe in the pelvic limbs, cervical pain and low carriage of the head. Clinical signs may range from only cervical pain (5-10% of patients) to paralysis. The owners commonly report a gradual onset, although the symptoms can sometimes occur or exacerbate more acutely. A slowly progressing hind limbs ataxia and/or paresis of the pelvic limbs is usually noted. Progression to thoracic limbs involvement with short stilted gait can also occur. A broad-based stance can be noticed in the hind limbs. Affected dogs often show a characteristic "disconnected" gait, where the thoracic limbs seem to advance at different rate. The disease is usually chronic progressive if left untreated. Prognosis is usually worse for dogs with chronic clinical signs and severe tetraparetics.

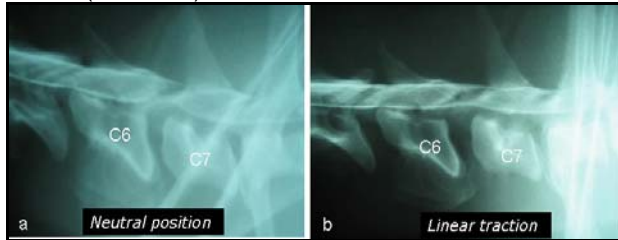
## Survey radiography

Survey radiography may be suggestive of DAWS but they are not conclusive. They are used as preliminary screening before more specific advanced imaging diagnostic techniques such as myelography, computed tomography (CT) and magnetic resonance imaging (MRI). Survey radiographies are useful to rule out potential other causes of cervical diseases such as vertebral fractures, subluxations, vertebral tumor, and discospondylitis. General anesthesia or sedation is necessary to obtain correct positioning of the dog. Mild deformity of the cervical vertebral

body and spondylosis deformans ventral to the intervertebral space may be seen, and narrowing of the intervertebral disc space is frequently seen. However, changes on survey radiographs do not always correlate with spinal cord compression. Some dogs with severe radiographic abnormalities will show no spinal cord compression on myelography or MRI and demonstrate no clinical signs. Survey radiographs may be normal in some dogs with DAWS.

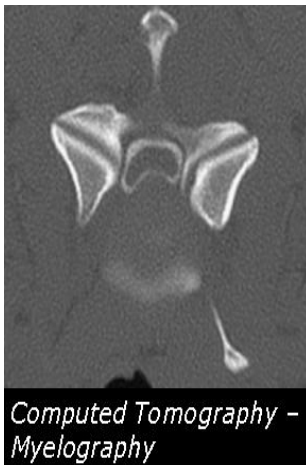### Advance Imaging Diagnostic (Myelography, CT and MRI)

Diagnosis of DAWS can be made by myelography with traction views (stress myelography) or MRI. In DAWS the extent of cord compression can vary with flexion, extension and linear traction (distraction).



*Lateral myelography of a 5-year old Doberman. Severe narrowing of the intervertebral disc space between C6-C7. Malformation of the cranioventral border of C7 is evident. Severe extradural spinal cord compression is noted (a). The severity of the compressive lesion reduces remarkably in size with traction (b)*

Owing to the risk of neurologic deterioration after these cervical manipulations during general anesthesia, only linear traction myelography or linear traction MRI views continue to be routinely used. Cross sectional computed tomography (CT) combined with myelography may also help to better visualize spinal cord compression and spinal cord atrophy.

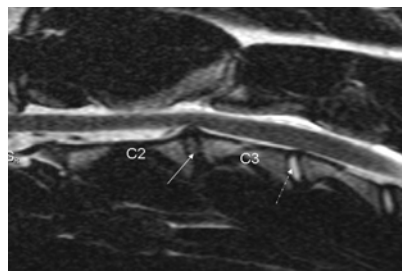


*Transverse plane of CT-myelography of a 6-year old mix-breed dog at the level of C5-C6. The subarachnoid space is filled with a radiolucent contrast material (white). The spinal cord (dark) is delineated by the surrounding subarachnoid space. A ventral spinal cord compression secondary to the protrusion of the intervertebral disc with the associated dorsal ligamentous structures are evident. The spinal cord lost its normal rounded appearance and is markedly distorted.*

Recently, MRI was shown to be more accurate and more informative than cervical myelography or CT-myelography. MRI better defines the site, severity and nature of spinal cord compression, and in allows visualization and characterization of intraparenchymal spinal lesions. Association between spinal cord MRI findings and histologic abnormalities has been documented. The possible complications that can be caused by myelography are not caused by the MRI, because this technique does not require the injection of a contrast medium into the subarachnoid space.

### Static versus Dynamic lesion

The concept of static and dynamic lesions was first established in 1982 and determination of the "dynamic" or "traction responsive" feature, in contrast to "static" lesions (such as extruded disc material, malformed facets, or deformed vertebral arches), has been suggested as being essential for the most appropriate operative technique. However, distinction between dynamic and static lesions is currently unclear, subjective, and dependent on personal opinion. However, it



*T2-weighted sagittal MRI of a 4-year old Rottweiler affected by DAWS. At the level of C2-C3, there is a complete loss of the hyperintense (white) CSF signal around the spinal cord with subsequent spinal cord compression. At this level, there is complete disc degeneration characterized as a total of hyperintensity of the disc that now appear grey (arrow), in contrast to a normal and healthy disc (dotted arrow). This dog was surgically treated by ventral slot. His neurological status slightly deteriorated 2 weeks post-operatively, most likely secondary to a further intervertebral disc space collapse. The dog progressively improved over the following 6 months.*

appears that 20% of the dog's weight is enough to produce sufficient traction, and it is unnecessary to use traction forces higher than 25% of the patient's weight. Generally, in-traction responsive lesion, the dorsal and/or ventral spinal cord compression may be reduced by the application of linear traction to the cervical spine which re-establishes disc width, flattens the relatively redundant soft tissue structures, and opens the narrowed foramina. In most dogs, 2-3 mm of distraction restores a normal disc width of 4-6 mm.

### Treatment - Medical treatment

Medical treatment with activity restriction and corticosteroids may be indicated in a normal dog with a first episode of neurologic deficits following minor trauma; otherwise, surgery is the treatment of choice. Conservatively treated dogs should have restricted activity for at least two months. In one study, where medical treatment was used, a successful outcome was achieved in 45% of the patients. In the same study, in 85 % of the dogs in which euthanasia was performed because of progression of DAWS, was carried out in the first year of diagnosis. This study concluded that conservative treatment for DAWS is associated with a guarded prognosis. In another study, that compared medical versus surgical treatment, it was found that 81% of dogs surgically treated (via ventral slot, dorsal laminectomy or distraction fusion) improved, compared to the 54% of dogs that improved with medical treatment.

### Surgical treatment

There are many surgical techniques described to treat DAWS, which can be broadly divided into two categories: direct access decompressive surgeries and distraction-stabilization surgeries. Direct access decompressive surgeries involve removal of the hypertrophied annulus fibrosus and dorsal longitudinal ligament via ventral slot or dorsal decompression via dorsal laminectomy.

**Dorsal laminectomy:** dorsal decompression is usually recommended for dogs with single dorsal lesions who do not respond to traction as well as do patients with multiple dorsal lesions. The major disadvantages are that extensive soft tissue dissection is needed, the ventrally located disk material cannot be removed, and there is significant, short term morbidity with deterioration of neurological status, which can cause considerable nursing problems in giant-breed dogs. In one study, fourteen of twenty dogs undergoing dorsal laminectomy had immediate decline in neurologic grade. Although dorsal laminectomy should not cause domino lesions, recurrence of clinical signs has been reported in 10% of dogs secondary to restrictive fibrosis.

**Ventral slot:** ventral decompression alone, can be technically challenging and exacerbates instability, particularly in extension. Ventral decompression may also result in further collapse of the disc space and exacerbates spinal cord compression with additional infolding of the legamentous structures and joint capsules. Bleeding from the venous plexus is also a major complication of ventral decompression, which in rare cases requires a blood transfusion. In over 20% of patients treated with ventral slot alone, failure to respond to treatment was associated with inadequate removal of disc material, which increased spinal cord compression as the intervertebral space collapsed at the

treated site. Collapse of the intervertebral space can also compress the nerve roots in the intervertebral foramen, which in turn may cause cervical hyperesthesia and focal spinal cord ischemia. Ventral decompression alone has also been associated with vertebral subluxation. In the long term this technique seems to be clinically effective and instability, if present, may be alleviated because after ventral decompression many of these interspaces will fuse, even without cancellous autografting.

**Distraction-stabilization:** distraction-stabilization-fusion techniques distract the vertebrae to stretch the hypertrophied tissue and relieve spinal cord compression; the vertebrae are then stabilized with appropriate implants and fusion is promoted with bone autografts (cancellous, cortical or corticocancellous) and cancellous bone allograft. Various techniques have been used to maintain distraction and/or graft retention to allow for bony fusion of the affected interspace. These include screws and washers, smooth pins, threaded pins or bone screws and polymethylmethacrylate (PMMA) bridges, interbody or intervertebral cement plugs, modified K-wire spacers with bone screws and PMMA bridge, metallic plates (stainless steel and titanium), plastic plates with unicortical and bicortical screws, and metallic plates with locking screws. Early implant failures with loss of distraction before fusion have been the most common cause of failure in distraction-stabilization techniques. Common complications include interspace collapse because ventral or dorsal migration of the graft, penetration of bicortical pins or screws into the vertebral canal with spinal cord damage or transverse foramen with vertebral arteries or nerve root compromise, fracture of bone cement bridges, pins, screws and plates, and various soft tissue complications such as esophageal erosion because of ventral hardware or PMMA prominence. These disastrous complications have caused some surgeons to rely only on direct ventral decompression for both static and traction-responsive lesions. Many authors using either direct or indirect decompression claim 70 - 90% success rate.

**Domino lesion:** Recurrence of clinical signs secondary to a "domino" lesion may occur as a late postoperative complication with any of these techniques. Recurrence can be caused by compression at the original site or by a domino lesion at an adjacent site. Domino lesions or adjacent segment disease are believed to be the result, at least in part, of abnormal stresses imposed on one intervertebral space by fixation of an interspace adjacent to it. These stresses can exacerbate any pre-existing subclinical instability, and produce either disc extrusion or hypertrophy of annular or ligamentous structures. Recurrence of paraparesis to tetraparesis occurs in up to one third of dogs after either ventral decompression or metal implant and bone cement fixation. It usually occurs between six months and four years after the original surgery, with a mean recurrence of around two years. A recent meta-analysis examining surgically treated DAWS dogs found an 80% short term success rate with about 20% of successful surgeries having significant recurrence after long term follow-up. The type of surgery performed (decompression versus distraction fusion), did not influence outcome. Given the high rate of surgical failure and long term recurrence, new methods are continually investigated for the treatment of DAWS in dogs.

**Cervical arthroplasty: Ventral decompression and placement of artificial disc.**

The goals of cervical arthroplasty is to preserve motion after neural decompression while providing distraction and stability. Ventral slot followed by the implantation of a cervical disc prosthesis in dogs with DAWS, has the potential to achieve the optimal goal of spinal decompression, restoration of the biomechanics at the surgical treated sites with sparing the adjacent vertebral motor units from the alterations in loading associated with ventral slot and distraction-fusion surgical techniques, which may eventually prevent the occurrence of a domino lesion. Additionally, advantages of cervical arthroplasty

over the standard ventral slot is that the artificial disc acts as a spacer preventing the early collapse of the vertebral space usually associated with ventral slot and/or vertebral subluxation at the treated site. Advantages of artificial disc implantation over pins or screws and PMMA distraction fixation techniques is the elimination of the potential complication associated with pin impingement on neurovascular structures.

In a preliminary in vitro study in dogs (Adamo et al. Veterinary Surgery 2007) it was concluded that cervical spine specimens with the implanted prosthesis have biomechanical behaviors more similar to an intact spine compared to spinal specimens treated with ventral slot and PMMA procedures. In a recent clinical pilot study (Adamo et al. Annual ACVIM Forum, Montreal, CA, 2009), for the first time an artificial disc in Titanium was implanted in two dogs clinically affected by DAWS. The artificial disc used was specifically designed and manufactured for the dog's cervical spine. The artificial disc used in this study is relatively easy to implant, it is cost-effective (its cost may be equivalent to the cost of the pins and PMMA), it does not require special instrumentation, and it could be applied to multiple sites if needed. In both dogs a good distraction at the treated site was achieved at the time of surgery, the implant was well tolerated and there were no signs of implant infection on the serial post-operatively radiographs. Both dogs had an excellent short and long term clinical outcome. It is likely that even in the event of loosing mobility at the treated site after the application of cervical prosthesis, this prosthesis may still be valuable because it may act as an internal vertebral distractor, while allowing to the rest of the spine to slowly and gradually accommodate to the new dynamic until a final stabilization occurs over time. Maintenance of distraction after direct spinal compression immediately and effectively relieves the mechanical compression caused by the redundant dorsal annulus and/or ligamentum flavum. The cervical prosthesis provide immediate distraction at the treated site which further decreased any residual compression from the redundant ligaments structures, and relieved spinal cord ischemia caused by compression of the vertebral spinal artery. The reopening of the narrowed intervertebral foramina further decompress the nerve roots, eliminating recurrent cervical pain. One dog was re-assessed with MRI 18 months post-surgery. In this dog all remaining cervical discs showed no signs of degeneration, and overall the MRI showed no significant changes relative to the MRI at the time of diagnosis. The possibility of performing MRI studies after implantation of this prosthesis, without interfering with spinal cord visibility, is an advantage over any other distraction stabilization techniques reported at this time. This allows, in the event of a recurrence of clinical signs, an accurate re-evaluation of the spinal cord at the same site as wells as at adjacent locations, for an early detection of domino lesion or any other spinal cord diseases. This preliminary clinical study proved the principle that cervical disc prosthesis in dogs could be a valuable method to treat DAWS in dogs.

**Conclusions**

Disc associated Wobbler syndrome is a relatively common cause of chronic spinal cord compression in adult large breed dogs including Rottweilers. This disease can be very challenging, both for the referring veterinarians and even for the specialists. DAWS is considered a surgical disease but the ideal surgical procedures still doesn't exist. Further studies are needed to improve the outcome of this devastating disease in dogs.

**Canine artificial disc project for DAWS - Donations**

*Because of the large scale shortage in research funding, private donations at this time are the main way to make progress in this field. We are looking forward to make a significant progress in the treatment of this devastating disease in dogs and even small donations can make a significative difference. Contribution can be made by either contacting directly Dr. Adamo at [flppadamo@yahoo.com](mailto:flppadamo@yahoo.com) or by sending a check to the order of Bay Area VNC, 208 Santa Clara Way, San Mateo - CA 94403, specifying that the donation is for the canine artificial disc project. Thank you in advance for your generous contribution.*