Frameless stereotactic CT-guided needle brain biopsy in dogs

Adamo PF, Lang AS

School of Veterinary Medicine, Department of Medical Sciences, University of Wisconsin, Madison WI, USA

Baltimore, ACVIM June 2005

Objectives

1. Design an inexpensive and reusable device
2. Developing a technique to simplify CT-guided brain biopsy in dogs

Device components

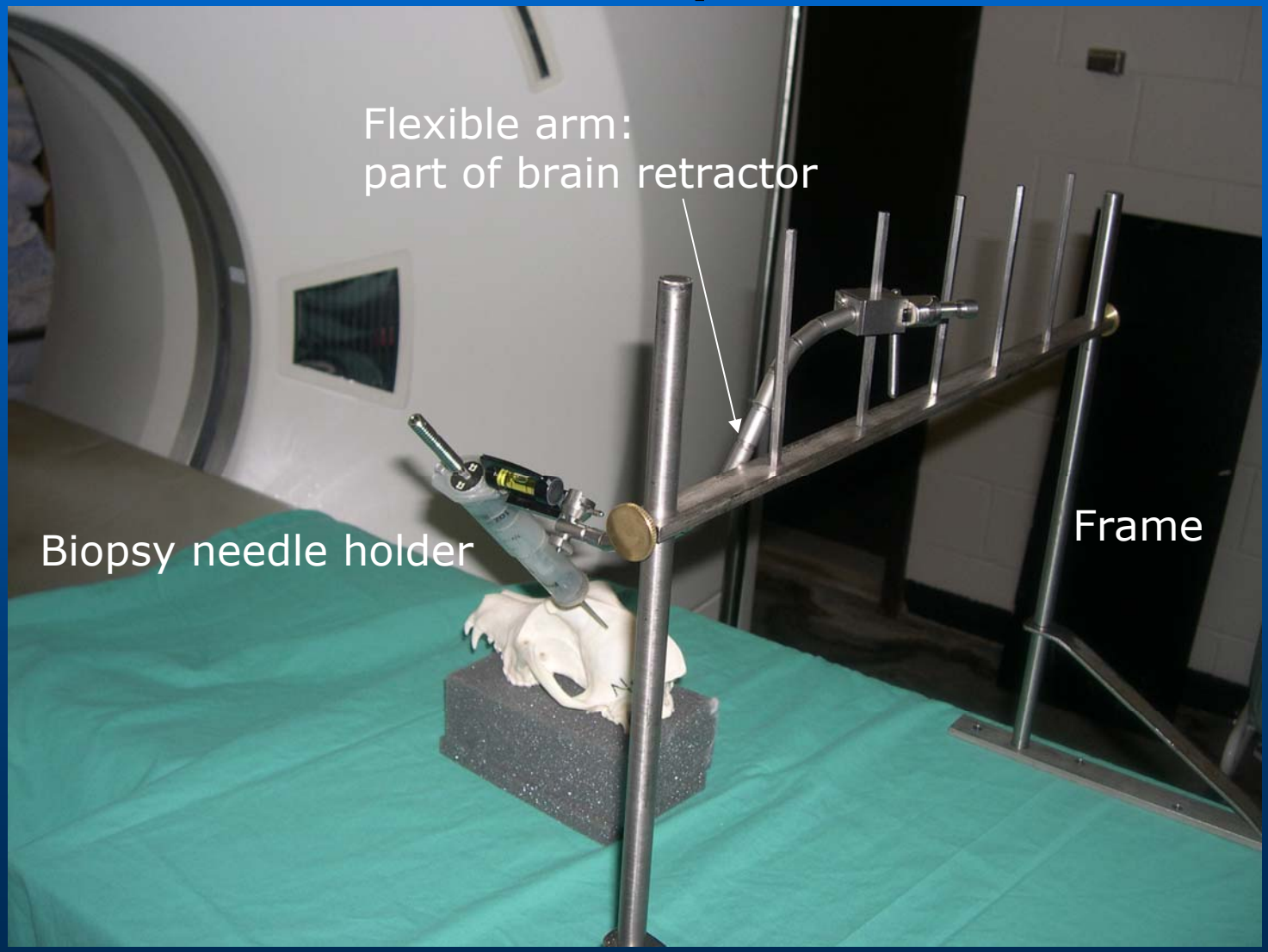

Device components

Biopsy needle

- ø2.1 mm Sedan Side-Cutting



Technique

- 5 cadavers – beagles
- Artificial forebrain lesion
  - Mini-burr hole – opposite parietal bone
  - Spinal needle 22G 3½ inch
  - 0.4 ml
    - 0.2 ml methylene blue
    - 0.2 ml Hypaque-76
- CT 3rd generation, GE
  - Soft-bone tissue window
  - 3-mm-thick sections
- Effectiveness
  - Macroscopic examination collected samples
    - Blue color confirmed that the target area was collected

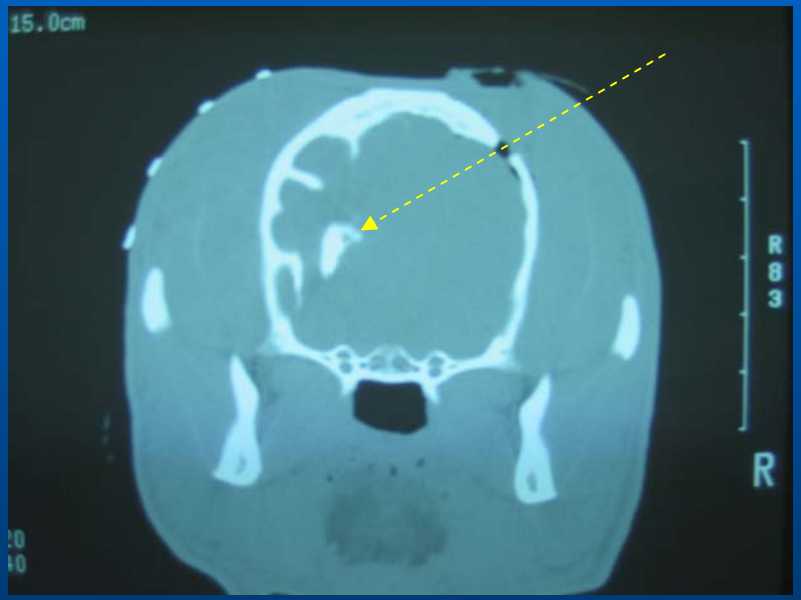

Technique

CT guided biopsy intrathoracic lesion

- Tidwell et al. 1994 refere……

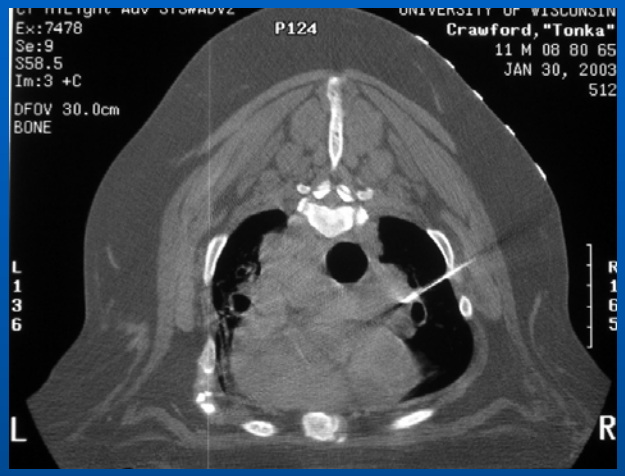

Clinical cases

- 4 dogs
- MRI: Forebrain lesion

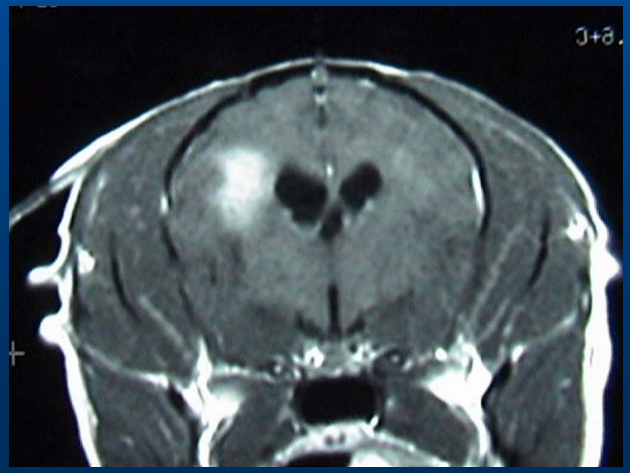

Technique

1. Head fixed in a stable position
   (tape, Vac-loc positioning mattress)

2. Target area localized on one transverse contrast CT image

3. Table position noted

Technique

4. Skin marked with black permanent marker corresponding to the gantry laser light at this position

5. Several barium marks applied at 90° along the ink line

Technique

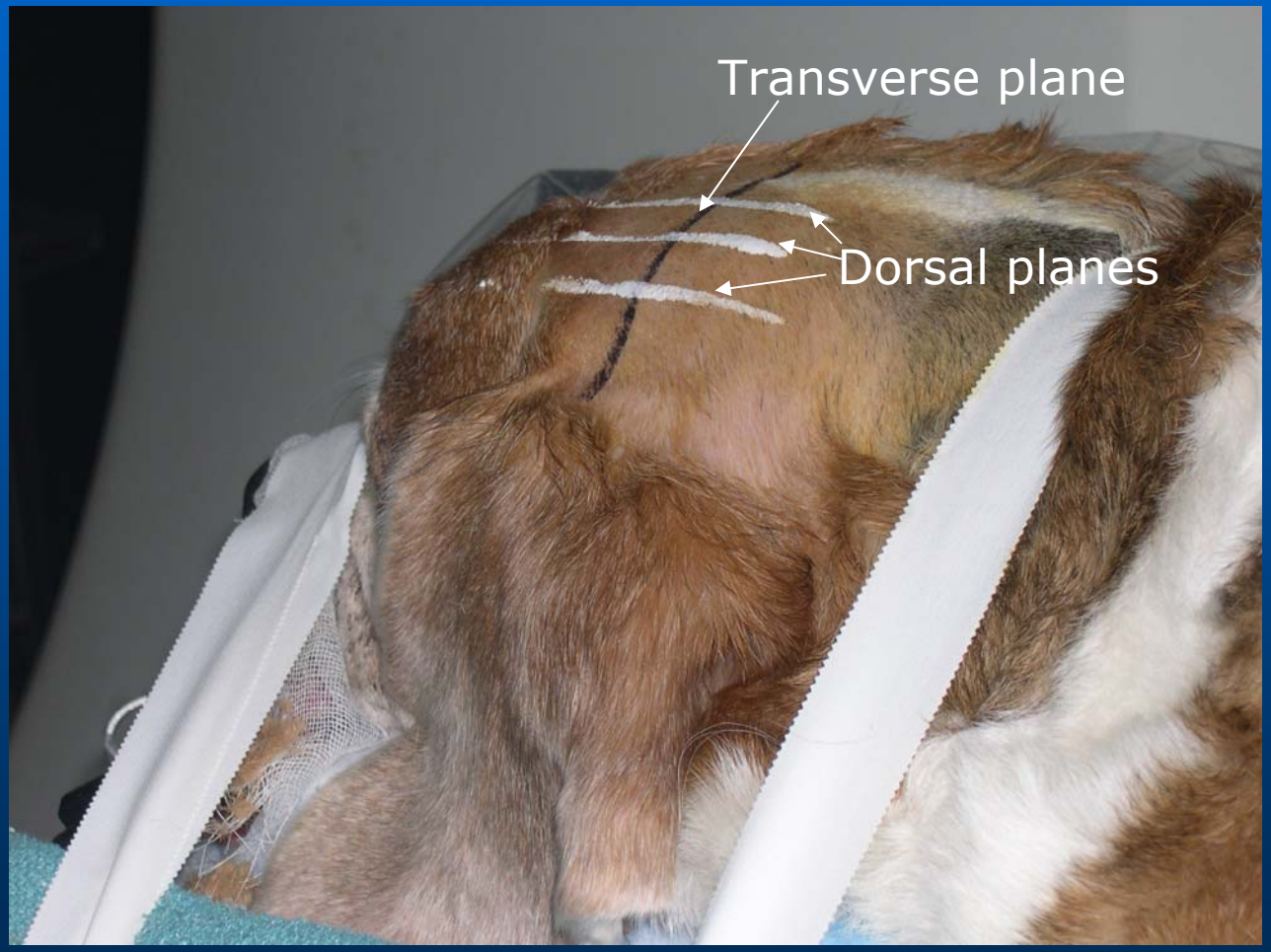

Technique

6. New scan with table set at the previous noted position
   - Lesion in the brain + barium lines over skin

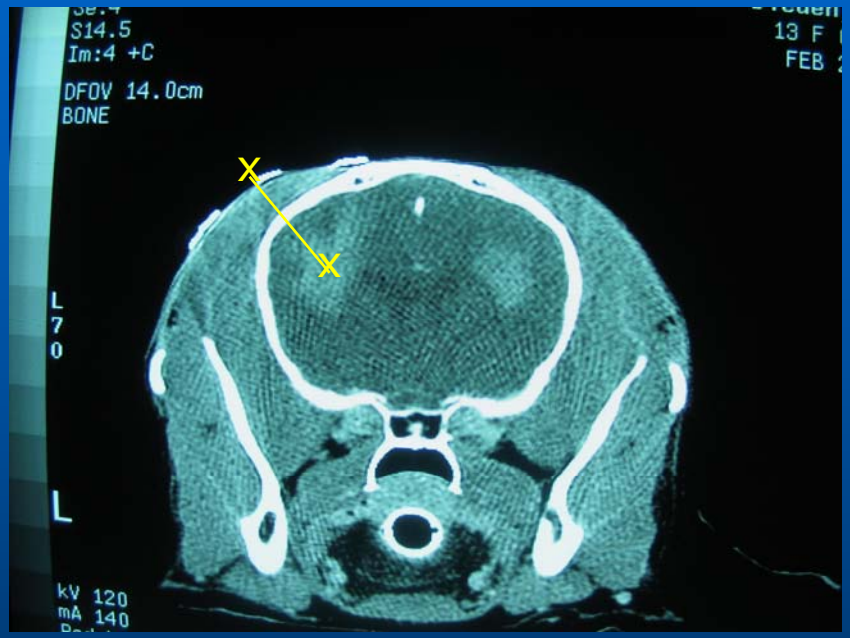

7. Barium line best aligned with the intracranial lesion
   - Reference point

Technique

8. Sterile scrub
9. Skin incision
10. Underlying muscles incision and dissection from the calvarium

11. 2 Gelpi retractors to maintain muscles retraction
12. Craniotomy: hand drill; ø3 mm bit

Technique

Mini-burr hole

Technique

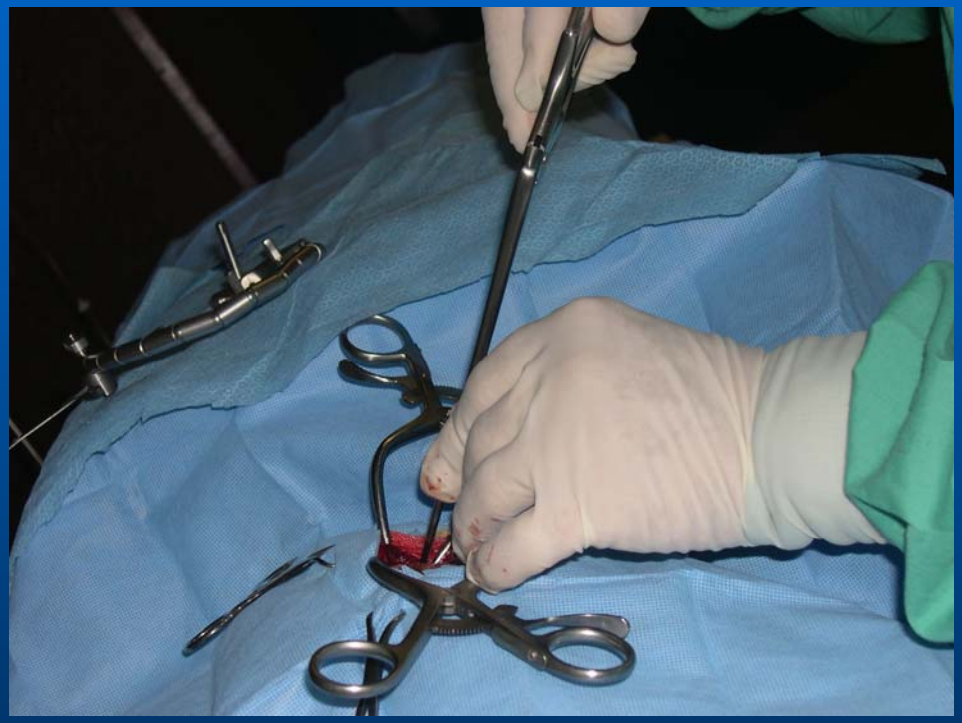

12. Craniotomy enlargement: 1 mm Kerrison Rongeur

Technique

13. Apparatus holding the biopsy needle mounted over the patient head

14. Tip of the needle faced in the craniotomy

15. Needle alignment to the transverse plan and to the lesion by using
    - CT gantry laser light

Technique

16. Table re-positioned at the same previous chosen target area

17. Final adjustment

    A) Oblique plan pointed to the lesion

    B) + Serial transverse CT scans

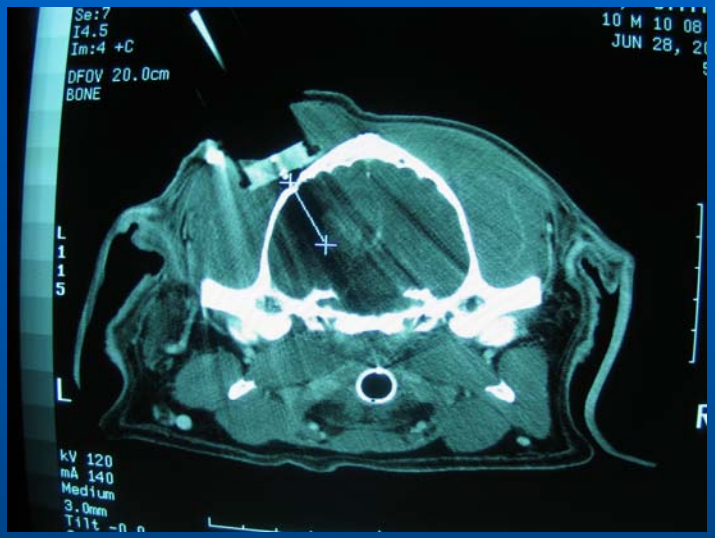

Technique

18. Distance
    from the tip of the needle to the center of the lesion

18. Needle advancement

19. CT scan to assure needle position within the lesion

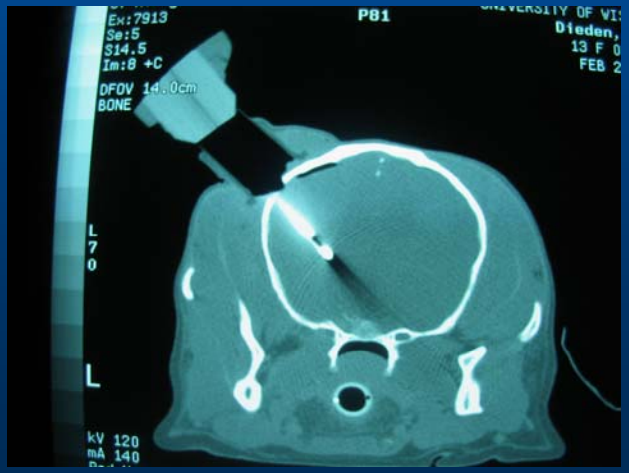

Technique

20. Negative pressure with 10 ml syringe

21. Inner biopsy needle
    - rotated to 180°
    - removed
    - flushed w/ air and sterile saline

22. 3 samples
    - distal, center, proximal
    - Cytology,
    - Histopathol
    - Bacteriol

Technique

- Duration 2.5-3 hrs
  - Including cytology time
- No complication
- Discharged after 48 hrs

Results

- Pathologic samples in all 4 dogs
- Diagnostic in 3 dogs
  - GME, Astrocytoma, Choroid plexus papilloma
  - In 2 dogs confirmed on necropsy

Discussion

Advantages

- No need for calculation of X,Y,Z axis coordinates
  - Direct visualization of needle tip relative to the target in the same CT image
- Errors in target trajectory can be adjusted as needed
- Reusable

Disadvantages

- Limited to forebrain lesions

Conclusions

- Effective
- Relatively simple
- Valid alternative to other techniques

- May be improved
- Further investigated in larger number of cases

Acknowledgements

- R.T. O'Brien
- S. Salwei
- J.T. Crawford
- W.M. Adams

- R.R. Dubielzig
- H. Steinberg

- R. Dickinson
- K. Friedrichs
- K. Young
- P. MacWilliams

- VMTH- University of Wisconsin